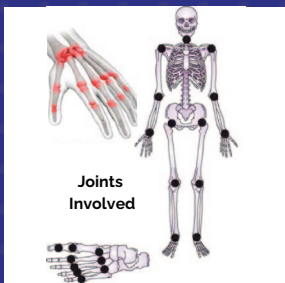


Rheumatoid Arthritis

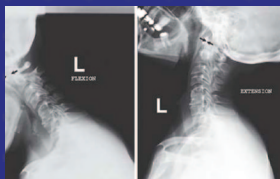Autoimmune joint destruction	ETIOLOGY	Inflammation induces formation of pannus (proliferative granulation tissue) which erodes cartilage and bone
-------------------------------------	-----------------	--

Pain, swelling, and morning stiffness lasting > 1 hour Symmetric polyarthritis	PRESENTATION	Improves with physical activity Systemic symptoms: fever, fatigue, weight loss
---	---------------------	---

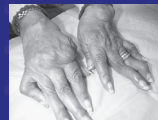

(UL): Reproduced with permission from Elsayes KM, Oldham SA: Introduction to Diagnostic Radiology. New York, NY: McGraw Hill; 2014.
(R, LL): Reproduced with permission from Imboden JB, Hellmann DB, Stone JH: Current Diagnosis & Treatment: Rheumatology, 3rd ed. New York, NY: McGraw Hill; 2013.

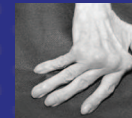JOINT FINDINGS



Cervical Involvement
Reproduced with permission from Mitra R: Principles of Rehabilitation Medicine. New York, NY: McGraw Hill; 2019.



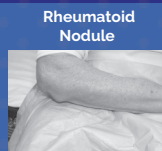
Swan-neck Deformity
Reproduced with permission from Imboden JB, Hellmann DB, Stone JH: Current Diagnosis & Treatment: Rheumatology, 3rd ed. New York, NY: McGraw Hill; 2013.



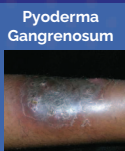Ulnar Deviation
Reproduced with permission from Mitra R: Principles of Rehabilitation Medicine. New York, NY: McGraw Hill; 2019.

Cyclic citrullinated peptide antibodies (Higher specificity!)	LABS	Rheumatoid Factor
--	-------------	--------------------------

NSAIDs Glucocorticoids Biologics	TREATMENT	DMARDs Disease-modifying antirheumatic drugs (ie, Methotrexate)
---	------------------	--



Rheumatoid Nodule
Reproduced with permission from Imboden JB, Hellmann DB, Stone JH: Current Diagnosis & Treatment: Rheumatology, 3rd ed. New York, NY: McGraw Hill; 2013.



Pyoderma Gangrenosum
Reproduced with permission from Usatine RP, Smith MA, Mayeaux EJ, Chumley HS: The Color Atlas and Synopsis of Family Medicine, 3rd ed. New York, NY: McGraw Hill; 2019. Photo contributor: Richard P. Usatine, MD.

COMPLICATIONS

**Secondary Sjögren's Syndrome
Felty Syndrome**

Lungs (ex. ILD) Eyes Cardiac