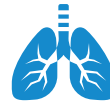



COPD



Clinical Presentation:

Emphysema

"Pink Puffer" - Late hypercarbia + hypoxia

Thin with muscle wasting and pursed lips

Productive cough >3 months for 2 years

VS.

Chronic Bronchitis

"Blue Bloater"—Early hypercarbia + hypoxia

Overweight and edematous

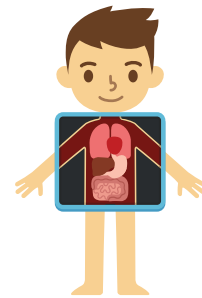
Terminal airway destruction + dilation

Diagnosis:

Pulmonary Function Tests (PFTs)

Gold Standard:

FEV ₁ /FVC	FVC	FEV ₁	TLC	Diffusing Capacity
Decreased	Decreased-Normal	Decreased	Normal-Increased	Decreased



Chest X-Ray:

Hyperinflated lungs, flat diaphragm with reduced lung markings

Arterial Blood Gas:

Hypoxemia with acute/chronic respiratory acidosis



Treatment:

Acute Exacerbation

Inhaled β -2 agonists
 Anticholinergics
 IV/Inhaled
 Corticosteroids
 Antibiotics
 Supplemental oxygen
 BiPap
INTUBATION if severe hypoxemia/hypercapnia

VS.

Chronic COPD

Inhaled β -2 agonists
 Anticholinergics
 IV/Inhaled corticosteroids
 Supplemental oxygen only if hypoxemic, right heart failure, or polycythemia
 Encourage smoking cessation + pneumococcal + flu vaccine

